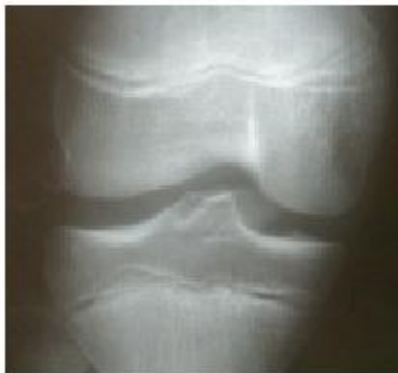
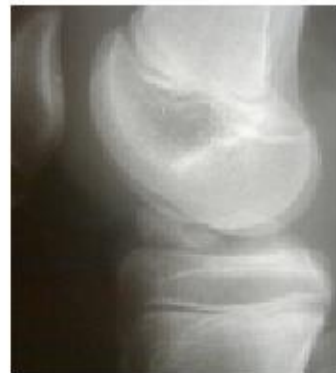
## TIBIAL EMINENCE FRACTURE

Tibial eminence fracture occurs less commonly in adulthood than in childhood. It is a fracture of the bony attachment of the Anterior Cruciate Ligament ( ACL) on tibia.



front Xray



lateral Rx

- In case of no or minimal displacement, the treatment consists on knee immobilisation for 1 month with a Radiologic control at 10 days, followed by a rehabilitation to restrengthen the quadriceps, recover the complete mobility within 2 to 3 months.
- In case of displacement, the “ duck billed” bony avulsion may lead to loss of extension and laxity of the A C L. Operation is needed to place the bone fragment in appropriate position and allow a perfect healing.

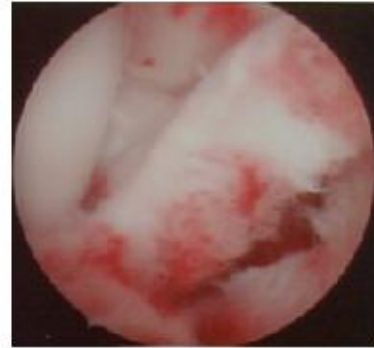
Many techniques have been proposed. The goal is to achieve fixation firm enough to strenghten ACL and to facilitate early rehabilitation.

The arthroscopic technique we use has some advantages as:

- to allow all types of ostéosynthesis
- to perfectly reduce the fracture
- to control ACL tension
- to evacuate hemarthrosis
- to allow an early rehabilitation.
- to shorten hospitalisation stay

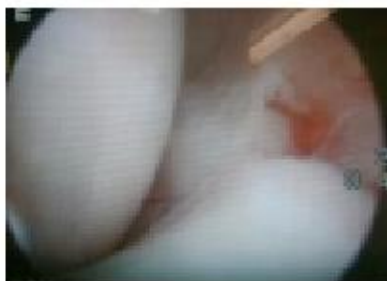### 1) ARTHROSCOPIC PROCEDURE

After cleaning the hemarthrosis, The knee is totally visualised and the fracture site is exposed. The bony avulsion is generally lifted upwards opened as an hinge.

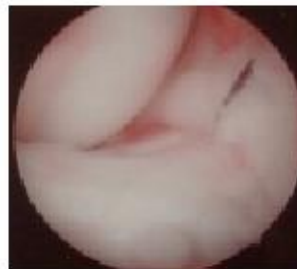

### 2) BONY REDUCTION

With a palpator, the fragment is anatomically positioned. Sometimes the anterior horn of the medial meniscus has slipped inside the fracture site and prevents any possibility of reduction. So we pass a thread up and down the meniscus through a needle inserted through the skin. This thread is then pulled to allow reduction of the bone.



meniscal entrapment



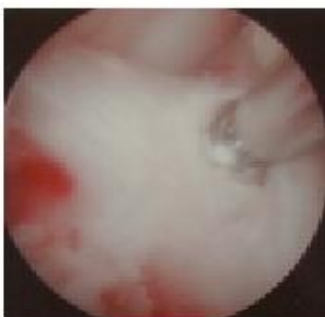
pulling meniscus



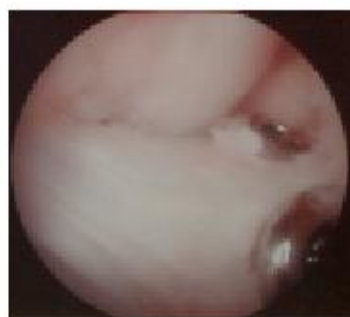
palpator & needle

### 3) OSTÉOSYNTHESE

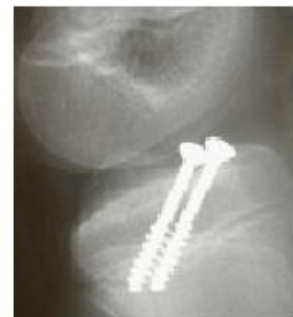Either a strong fragment is available, and it is possible to fix it with one or two screws, or the fragment is brittle, and it is better to fix it with a wire loop. In that case, small tibial tunnels will be drilled through the anterior cortex of the tibia through a small skin incision.



one screw



two screws



control profile Rx