

Dr Alain CAZENAVE (MD)

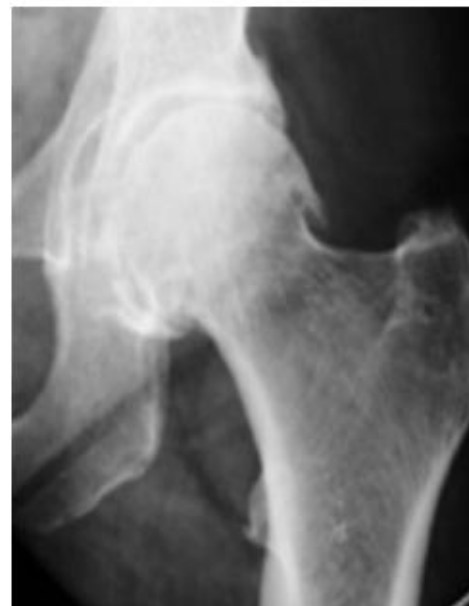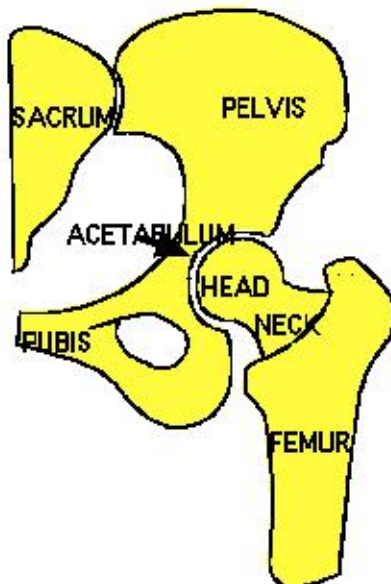
Orthopaedic Surgeon
Sports traumatology

www.orthopale.com

PRINCIPLES OF TOTAL HIP ARTHROPLASTY

THA is one of the most successful surgeries performed with excellent 15-20-year survivorships routinely reported in large series by multiple surgeons. Over the past few years, modified surgical techniques such as capsular repair, the use of alternative bearing surfaces, and minimally invasive techniques have become increasingly popular.

It is widely used in the treatment of severe hip osteoarthritis, avascular necrosis, rheumatoid arthritis, gout and other general arthritic conditions.



COXARTHROSIS -LEFT HIP

When the medical treatments (antalgic and anti-inflammatory medications, heel wedges, weight reduction, activity modification, the use of ambulatory aids, intra-articular corticosteroid or viscosupplementation (eg, Synvisc; Genzyme Corp; Cambridge, Massachusetts, and Hyalgan; Sanofi-Synthelabo; New York, NY) injections, physiotherapy have failed, time is coming to implant a prosthesis to relieve pain and to restore hip function.

BEARING SURFACES

Two types of bearing surfaces are preferable:

- metal on polyéthylène (PE) : the older, well known, and secure one.

In case of polyethylene wear it is easy to only replace it by a new polyethylene socket.

- ceramic on ceramic: the best association in term of wear but this material is brittle and may breaks in case of fall.

We prefer to use a secured procedure with a metal on PE.

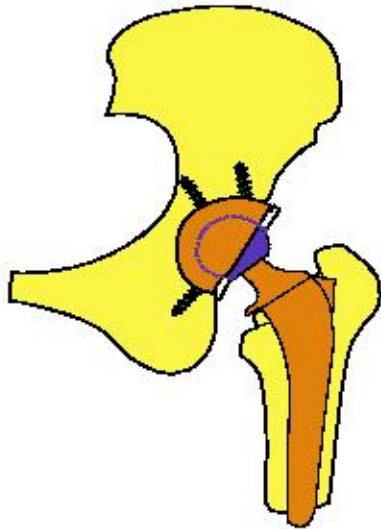


PROSTHESIS COMPONENTS

The device is composed of :

- a fixed femoral stem and
- a fixed acetabular metal-back component articulating by the intermediary of
- a polyéthylène socket insert and
- a ball-head replacing the two damaged articular surfaces of the acetabular surface and the femoral heads.

The size of the femoral chrome-cobalt head size is 28 mm.



The modularity of this THA (stem, neck & head in 3 separate components instead of only one component) presents advantages:

- it allows an easy revision in case of changing PE socket or femoral head letting the femoral stem well anchored : it is a small operation
- it allows to better adapt the length and orientation of the femoral neck during the primary or revision surgery.

It is a safe device implanted for 20 years without any breakage or dislocation of the modular components.

CHECK-UP BEFORE SURGERY

Before deciding the operation, X-Rays of the pelvis and of the hip (frontal and sagittal view) and a clinical examination are necessary to evaluate the degree of the anatomic modifications of the hip, the surgical difficulties, and the functional outcome of the hip.

In order to detect vital risk for anesthesiology, and to assess a potential risk of post-operative complication in a short or long term follow-up, a medical questionnaire checking list is needed to be accepted by the surgeon and his team.

factors increasing risk of infection

- **Obesity** is associated with a higher risk of infection. Individuals with a body-mass index (BMI) >35 had a 2.1 times greater risk of infection compared with those with a lower BMI
- **patients with osteonecrosis and rheumatoid arthritis** had a 2.2 times greater risk of infection compared with those with osteoarthritis.
- **diabetis** : it must be balanced to minimize the risk of infection
- **previous infection of the joint**
- **arteritis** : decreases blood vascularisation
- **tooth infection** : a panoramic dental X-Ray and treatment of dental problems is necessary to eliminate a potential risk of infection

factors increasing risks for medical complications

- American Society of Anesthesiology (ASA) scores > 3 is at risk.
- Previous deep venous thrombosis is a predisposing factor to recurrent episode

HOSPITALISATION

Admission in Institut CALOT takes place the day before operation. You will stay 7 days in the surgical department of orthopaedics and then 7 days in the rehabilitation center.

SURGICAL TECHNIQUE

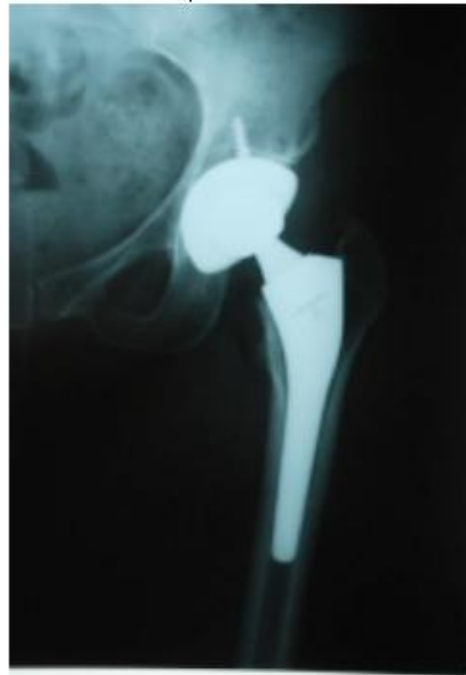A postero-lateral approach with a **Mini Invasive Technique** is used: Attempt is made to keep incision length as small as possible without compromising exposure and components placement. In général, incision length averages 9 to 12 cm .

Once the bone cuts and reamings have been made, the prosthetic trials are implanted to test carefully adequate positioning, soft-tissue tension, and stability after reduction of the components. Modification may be possible according to the multiple possibilities given by the modular necks and ball-heads of multiple dimensions (24 positionis allowed). The definitive devices are then implanted.

Wound closure is achieved with absorbable "vicryl" sutures and a suction drainage, and skin closure with staples. A light gauze, cotton wool, and crepe dressing is applied.

This **Mini invasive posterior approach**

limits the traumatism of the muscles, enables a reduction of intraoperative bleeding and in postoperative pain and allows more rapid rehabilitation.



X-Ray of THA

POSTOPERATIVE CONSIDERATIONS

Day of operation

The patient is mobilised at approximately 4 h post-op, under physiotherapist supervision. Straight leg raising exercises are encouraged, and a pillow is placed between the two limbs to prevent any position able to provoke dislocation.

Intravenous patient- controlled-analgesia (PCA) systems or other analgesic schedule plan is started for overnight analgesia.

First postoperative day

The postoperative haemoglobin level is measured. The PCA was discontinued, but only after commencement of the pre-prescribed analgesic regimen, to ensure that pain levels is well controlled throughout the recovery period. Regular anti-emetics are continued, and the patients undergoes further range of motion, and exercises twice a day under control of the physiotherapist. Walking with a frame is started.

Second, third, fourth postoperative day

The drainage removed. The patients continued to walk with the assistance of a frame or walking sticks. Active exercises are encouraged.

fifth and subsequent postoperative days

The patients is encouraged to climb steps, and to walk safely with two sticks and climb stairs independently.

Functional exercises and advices are shown to prevent bad positioning of the limb. Exercises of muscles reinforcement, and stability are performed.

COMPLICATIONS

Even with a careful act performed by a perfectly trained team, any complications may happen the same as in every surgical act. These are exceptional; The list below is not exhaustive.

- **fissuration** of the femur or acetabulum when impacting the components during operation induced by a weakened osteoporotic bone. This is generally without any consequence on follow-up and final result.

- **dislocation** is a rare but real problematic complication for all the surgeons even with good technique and good positioning of the implants. It may come because of the post-operative weakness of the gluteus muscles during the first three months period. Advice and functional education are given to prevent it. In case of happening, the reduction is performed under general anesthesia.

- **Infection** is one of the most dreaded complications of total hip replacement. The efficacy of prophylactic measures and risk factors play an important role:

- prophylactic measures: laminar flow, body suits, drains, surgical time (length), surgeon volume, and hospital volume, the use of preoperative antibiotics.

- detection and treatment of risk factors: - Obesity, diabetes, pre-op treatment of dental or urinary infection.

In case of happening, reoperation for cleaning and removal of the THA is needed; a new THA may be reimplanted immediately during the first 3 weeks post-op period.

- **paralysis of sciatic nerve** is exceptional but may be seen in case of compression by an hematoma; a re-operation is needed rapidly. Sequellae as partial palsy may be seen temporarily.

- **limb length discrepancy**: It is a classical postoperative feeling of the patient up the gluteus muscles strengthen even with a perfect bone balance. 5 mm difference is a physiological difference with no consequence on the normal function. In case of preoperative difference it is not always possible to correct it. Heel wedge may be given.

- **phlebitis**: preventive measure (early mobilisation, anti-thrombotic socks, low Weight Molecular Heparin anti-embolic prophylaxis for 6 weeks) and systematic echodoppler control at 7th day allow the risk to be minimized; in case it happens, an anticoagulation treatment is started and rehabilitation is slowed.

LONG TERM FOLLOW-UP

- **wear** is not a short term problem: a regular follow-up control is necessary every three years. Overweight and overuse are favorable factors for polyethylene wear, or breakage.

- **loosening** is not a short term problem: a regular follow-up control is necessary every three years. Overweight and trauma are favorable factors for bone loosening

- **post-operative requirements**

- Do not overweight to prevent wear and loosening.

- Help with your arms for standing up from a chair, and climbing stairs to lessen the strains on the prosthesis.

- Tell your doctor or dentist that you have a prosthetic device so that in case of infection he gives you adequate treatment with antibiotics to prevent an infection of the prosthetic joint that may occur even years after your surgery.

- Do exercises at home and at least walk 30 mn a day. Sports activities are possible according to comorbidity, age, range of motion and stability; waiting 3 to 6 months after a THA is a current recommended waiting time for return to sporting (see special form).